

Analysis and implementation of kidney stones detection by applying segmentation techniques on computerized tomography scans

Mua'ad M Abu-Faraj*

Faculty of Information Technology and Systems

The University of Jordan

Aqaba

Jordan

m.abufaraj@ju.edu.jo

Mohammad Zubi

Faculty of Business

Al-Balqa Applied University

Al-Salt

Jordan

mohammad.zubi81@bau.edu.jo

Abstract. Kidney stone disease is one of the risks for life throughout the world and majority of people with stone formation in kidney at the initial stage do not notice it as disease and it damages the organ slowly. Current estimation is that there are 30 million people suffering by this disease. There are different imaging techniques for diagnosing kidney diseases, such as CT images, X-rays, and Ultrasound imaging. In this study we explored the deployment of three segmentation techniques using matlab to examine the kidney area, and to enhance kidney stone detection. The segmentation techniques under investigation are: threshold based segmentation, watershed based segmentation, and edge based segmentation.

Keywords: image processing, segmentation, computerized tomography, kidney stones.

1. Introduction

There are various imaging techniques that can be used in the medical practice such as computed tomography (CT) scan, X-rays, and magnetic resonance imaging (MRI). CT scans are one of the most widely available imaging techniques. These techniques are used for diagnosis and follow-up of different kidney abnormalities. These abnormalities comprise stone disease, kidney cysts, hydronephrosis (blockage of urine), congenital anomalies, as well as urinary tract tumors. Moreover, successful management and surgical treatment of such conditions depends largely on accurate identification of such anatomical details. The detection of kidney stones using ultrasound imaging is a highly challenging task and is largely operator dependent as they are of low contrast and contain speckle

*. Corresponding author

noise. This challenge is overcome by employing other imaging techniques. In fact, non-contrast enhanced CT scan of the urinary tract is considered the gold standard of stone disease (Petrik, et al., 2016). The performance of CT scan is not only superior to all other imaging modalities but also provides various vital information that play a crucial role in patient counseling in treatment decision such as stone density, structure of the stone and skin-to-stone distance (Viswanath and Gunasundari, 2015).

The images obtained by X-ray or CT in adverse conditions may be contaminated with noise that can affect the detection of diseases, abnormality or cancerous cells. A large number of image processing techniques (filters) have been proposed to remove noise. These techniques depend on the type of noise present in the image (Sanchez et al., 2012).

The operation of producing the estimated clean, original images out from noisy/corrupt images is called image restoration. There are many forms of corruption on images, such as: motion blur, camera noise, and camera misfocus (Banham and Katsaggelos, 1996). The goal of restorative image investigation is to procure helpful data about the body organs and the medical courses of action needed. This can be done by utilizing outer and inside wellsprings of vitality, kidney image analysis performed using CT scans. CT scans are preferred method to take images of the kidney because of its straightforwardness, convenience and cost viability (Ebrahimi and Mariano, 2015).

An important source of information for kidney imaging is the presence and distribution of micro calcifications in the kidney, this anatomical information can be obtained with high resolution technology using CT scans, As yet there is no comprehensive imaging modality for all CT scan applications and needs, despite the fact that the capacity to mechanize and examine restorative pictures gives a capable intends to help doctors; subsequently computer projects, handling techniques that get the information and data from medicinal imaging scanners must be painstakingly created to save and improve the most imperative clinical data as opposed to presenting extra curios. The ability to improve diagnostic information from medical images can be further enhanced by designing computer processing algorithms, application and software intelligently, that is why we proposed an application based on matlab software to clarified boundaries for stones in kidney (Ebrahimi and Mariano, 2015).

The compelling question is: why do physicians treat kidney stones? First of all, this disease is usually a painful condition where pain medication is a temporary measure and a definitive measure should be undertaken i.e stone removal. Moreover, pain medications are not effective to alleviate pain. Interesting, results from historical landmark observational studies (Blandy and Singh, 1976). In 1970s reported a 10-year mortality rate of up to 30% in patients with large kidney stone (staghorn stone) who were treated conservatively (without surgical removal). Additionally, one quarter of these patients suffer from severe urinary tract infections that have significant impact on kidney function. (Rous and Turner, 1977). In this paper we aim to provide physicians with accurate

results related to the existence of kidney stones on the CT images, using efficient segmentation techniques.

2. Literature review

X-rays and Ultrasound imaging are considered low cost imaging techniques. While CT are considered high cost technique. The researchers in (Vasanthselvakumar, et al., 2017) has focused their studies on applying image processing techniques on Ultrasonic images, they have applied an automatic detection and classification of various diseases such as stone, cyst and cancer masses present in the pelvic region of the kidney.

While other researchers have focused on analyzing the images resulted by using MRI systems (Youngwoo, et al., 2016), and (Hamed and Fei, 2013). The authors in (Youngwoo, et al., 2016), have developed an automated method for segmentation and a method to provide the measurements of kidneys from magnetic resonance images in patients with autosomal dominant polycystic kidney disease, the authors also assessed the performance of the automated method with the reference manual segmentation method. In (Hamed and Fei, 2013), the authors have provided an automatic segmentation of the kidney in 3D MR images, by extracting texture features and statistical matching of geometrical shape of the kidney. The researchers in (Altintas, et al., 2010) have used x-ray images to detect kidney stones. The authors in (Tulin and Das, 2017) and (Natarajan, et al., 2013) have applied image processing techniques on CT scan images.

Image segmentation is the process of partitioning a digital image into multiple segments. The goal of segmentation is to simplify or change the representation of an image into something that is more meaningful and easier to analyze. Several image segmentation techniques have been developed by the researchers in order to make images smooth and easy to evaluate. In (Tulin and Das, 2017), the authors aim to remove the Gaussian noise from the abdominal CT scan images and segment the kidney region from this abdominal area to make a size measurement and to characterize the difference between healthy and diseased kidney. In (Natarajan, et al., 2013), the authors have developed an approach for extracting kidney in abdominal CT scan images. The images have been divided into two stages. In the first stage a template evaluation method has been developed for extracting the desired region in an image on the basis of properties of an organ, which helps in processing to a confined region and is an automated process. The second stage uses the concept of intensity values of a pixel and separates the desired region from the original image on the basis of a computed threshold range. In addition to this, the authors have used a set of morphological operations for fine coarse kidney segmentation and various filters for removing noise from an image. In (Ebrahimi and Mariano, 2015), the authors have provided a development of a semi-automated program that used image processing techniques and geometry principles to define the boundary,

and segmentation of the kidney area, and to enhance kidney stone detection. It marked detected kidney stones and provided an output that identifies the size and location of the kidney based on pixel count. The program was tested on standard Kidney Urine Belly (KUB) CT scan slides. The KUB CT scan slides who were divided into two groups based on the presence and absence of kidney stones in their hospital records.

3. Data and methodology

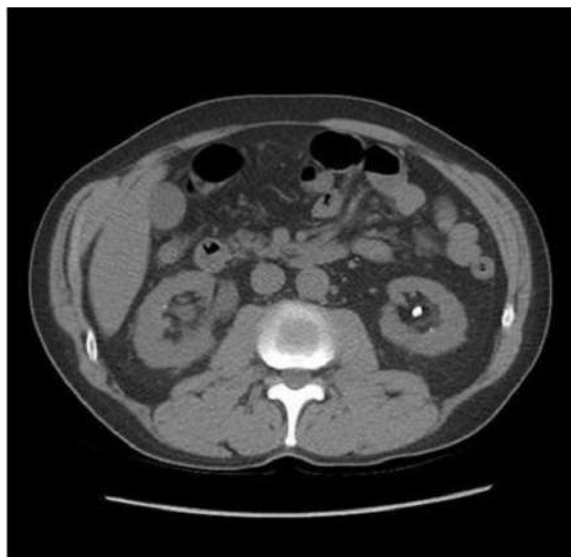


Figure 1: The Original Image

Matlab is a high-performance language for education and research as it integrates computation, visualization and programming in an easy-to-use environment where problems and solutions are expressed in familiar mathematical notation and also it has toolboxes for signal processing, neural network, image processing, database etc. Matlab software was used to implement the algorithm, since Matlab Image Processing Toolbox is a collection of functions that extend the capability of the Matlab numeric-computing environment. The toolbox supports a wide range of image processing operations, such as Image analysis and enhancement. Region of interest operations, linear filtering and filter design (Beucher, et al., 1990). All the functions and equations used in this study are from Matlab image processing toolbox.

The CT scan images are taken from (Kidney Stones, 2018), the original image was segmented by threshold, edge-based segmentation, and watershed segmentation, the original image is shown in Fig.1. There are many segmentation techniques as shown in Fig.3. In this paper we have applied three segmentation techniques on the gray scale image after applied Gaussian filter twice on

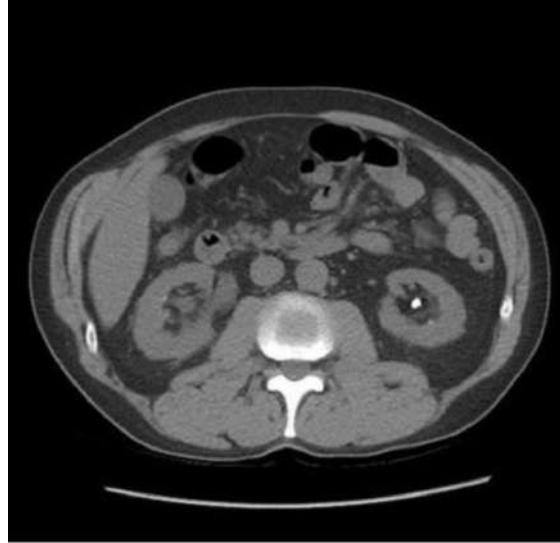

Figure 2: Gray Scale Image

original image shown in Fig.2. These segmentation techniques are Edge based segmentation, Watershed segmentation, and Threshold based segmentation.

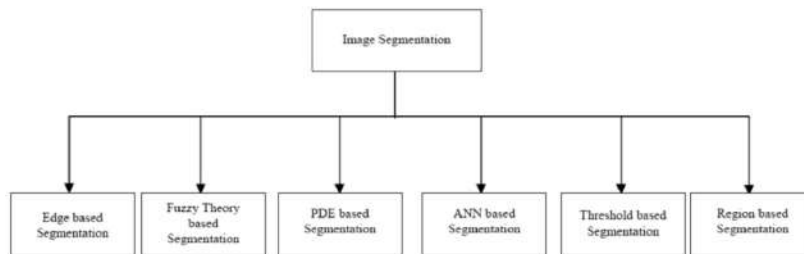


Figure 3: Image Segmentation Techniques

3.1 Edge based segmentation

All images produced in this paper were processed using matlab software. As shown in Fig.4 illustrate steps edge based segmentation method started by reading image, then detecting the entire cell, two cells are presented in this image, but only one cell can be seen in its entirety, this cell will be detected. Another word for object detection is segmentation. The object to be segmented differs greatly in contrast from the background image. Changes in contrast can be detected by operators that calculate the gradient of an image. The gradient image can be calculated and a threshold can be applied to create a binary mask containing the segmented cell. First, we use edge and the Sobel operator to calculate the threshold value. We then tune the threshold value and use edge

again to obtain a binary mask that contains the segmented cell. The next step is to dilate the image. The binary gradient mask shows lines of high contrast in the image. These lines do not quite delineate the outline of the object of interest. Compared to the original image, you can see gaps in the lines surrounding the object in the gradient mask. These linear gaps will disappear if the Sobel image is dilated using linear structuring elements, which we can create with the `strel` function. The binary gradient mask is dilated using the vertical structuring element followed by the horizontal structuring element. The `imdilate` function dilates the image. Filling the interior gaps is the next step. The dilated gradient mask shows the outline of the cell quite nicely, but there are still holes in the interior of the cell. To fill these holes, we use the `imfill` function. Then the connected objects in border should be removed. The cell of interest has been successfully segmented, but it is not the only object that has been found. Any objects that are connected to the border of the image can be removed using the `imclearborder` function. The connectivity in the `imclearborder` function was set to 4 to remove diagonal connections. The next step is smoothening the object. Finally, in order to make the segmented object look natural, we smoothen the object by eroding the image twice with a diamond structuring element. We create the diamond structuring element using the `strel` function. An alternate method for displaying the segmented object would be to place an outline around the segmented cell. The outline is created by the `bwperim` function.

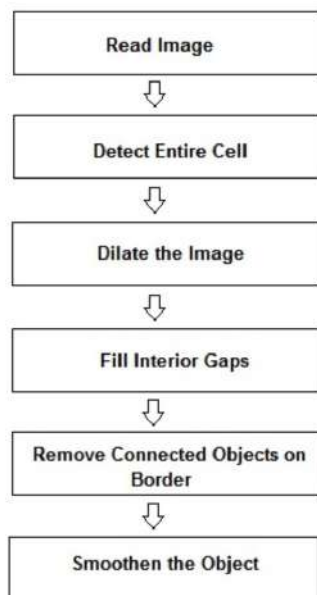


Figure 4: Edge Based Segmentation

3.2 Watershed based segmentation

There are many category watershed segmentation techniques. In this paper; marker controlled watershed segmentation has been applied sequential steps on the original 3D image as Illustrate in Fig.5 Watershed segmentation has been used to separate touching objects in an image. The watershed transform finds "catchment basins" and "watershed ridge lines" in an image by treating it as a surface where light pixels are high and dark pixels are low. Segmentation using the watershed transform works better if you can identify, or "mark," foreground objects and background locations. Marker-controlled watershed segmentation follows the following procedure: compute a segmentation function; where the image whose dark regions are the objects you are trying to segment. The next step is to compute foreground markers, there are connected blobs of pixels within each of the objects. Then we should compute background markers to remove the pixels that are not part of any object. Applying the segmentation function so that it only has minima at the foreground and background marker locations. The last step is to compute the watershed transform of the modified segmentation function.

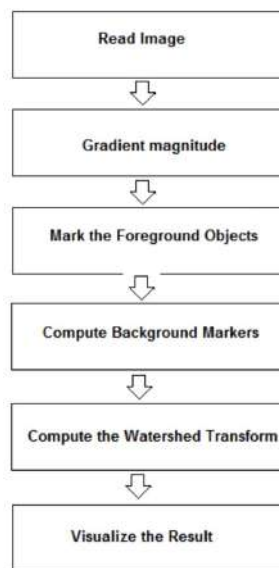


Figure 5: Marker Controlled Watershed Segmentation

3.3 Threshold based segmentation

Thresholding is the simplest method of image segmentation. From a gray scale image, thresholding can be used to create binary images. Binary images are produced from color images by segmentation. Segmentation is the process of assigning each pixel in the source image to two or more classes. If there are

more than two classes, then the usual result is several binary images. In image processing, thresholding is used to split an image into smaller segments, or junks, using at least one color or gray scale value to define their boundary. The advantage of obtaining first a binary image is that it reduces the complexity of the data and simplifies the process of recognition and classification. The most common way to convert a gray level image to a binary image is to select a single threshold value. The input to a thresholding operation is typically a gray scale or color image. In the simplest implementation, the output is a binary image representing the segmentation. Black pixels correspond to background and white pixels correspond to foreground (or vice versa). This method of segmentation applies a single fixed criterion to all pixels in the image simultaneously. There are three types of thresholding algorithms.

- Global thresholding
- Local thresholding
- Adaptive thresholding

4. The results

In many cases kidney CT scan images cannot give enough information to the physicians; these information includes: the size, position of stones and other issues. In this paper, the experiments focused on detecting and clarifying stones in CT scan images using three methods. The first step is applying enhancement on image as we mentioned before by using double Gaussian filter, and convert the original image to gray scale; this approach is used in edge base segmentation and thresholding segmentation. Segmentation methods are based on gray intensity on image while all medical images are gray scale.

4.1 Edge based segmentation

In edge-base segmentation technique; a connected pixel that is found on the boundary of the region is called an edge, so these pixels on the edge are known as edge points. Edge can be calculated by finding the derivative of an image function. Some edges are very easy to find. These are: Ramp edge, Step edge, Roof edge, Spike edge. Step edge is an abrupt change in intensity level. Ramp edges a gradual change in intensity. Spike edges a quick change in intensity and after that returns immediately to an original intensity. Roof edge is not instantaneous over a short distance. Edge based image segmentation method falls under structural techniques. As show in in the figures below, the result from Dilated Gradient Image and Binary Gradient Image is better than thresholding image. Kidney stone is cleared and surrounded by edge, edge-base segmentation is also fit for two dimension images.

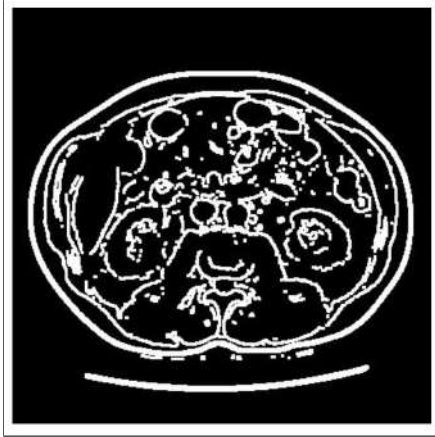


Figure 6: Dilated Gradient Image

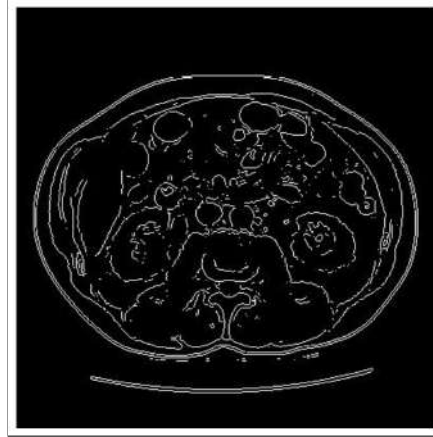


Figure 7: Binary Gradient Image

4.2 Marker-controlled watershed segmentation

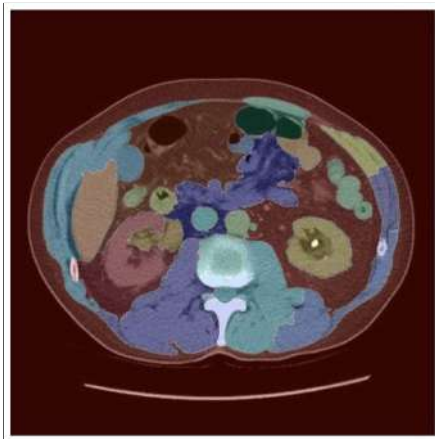

Figure 8: Superimposed Image

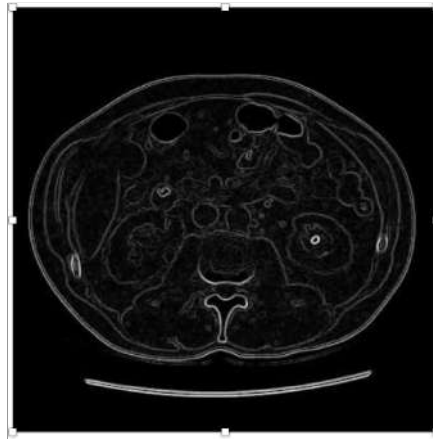


Figure 9: Gradient Magnitude Image

In watershed Segmentation technique after applying the double Gaussian filter of the three dimension image (topography surface) and then start filling images by water, this is done to create Dam. This technique give us notifications about topography of images (high and low places), this technique will colored segments with different color, its helpful for physician to detect and allocate stones in kidney as show in Figure 13.

4.3 Threshold segmentation

In threshold based segmentation: images will change pixels color that convey value of intensity to 1or 0 based in thresholding variable T , as given in the equation 1. As seen in Fig. 15, the result after applying thresholding segmentation

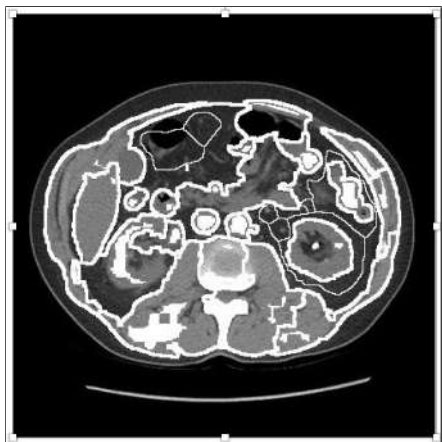

Figure 10: Markers and Object Boundaries Superimposed on Original Image

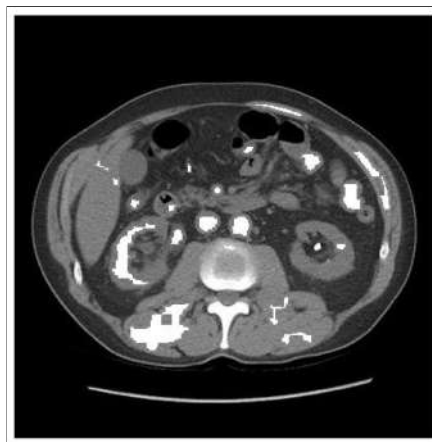

Figure 11: Modified Regional Maxima Superimposed on Original Image

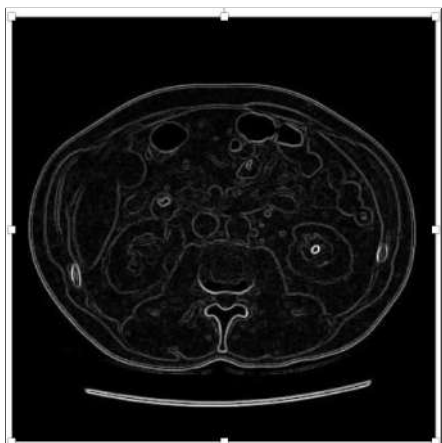


Figure 12: Gradient Magnitude Image

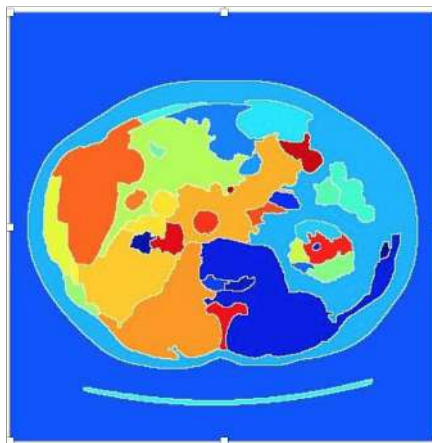


Figure 13: Colored Watershed Matrix Image

technique on gray scale filter. Fig. 15 displays stones in kidney but its not clear when its compared with other techniques. Thresholding is segmentation technique suitable for two-dimension images.

$$(1) \quad q(x, y) = \begin{cases} 1, & \text{if } p(x, y) > T \\ 0, & \text{if } p(x, y) \leq T. \end{cases}$$

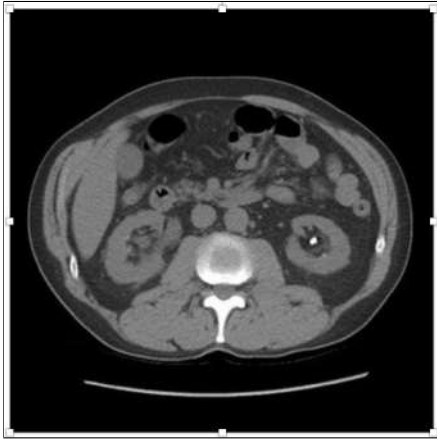

Figure 14: Gray Scale Image

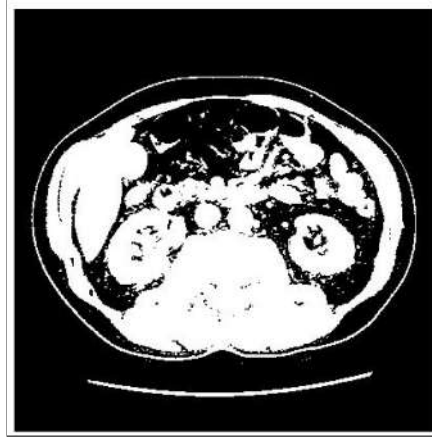

Figure 15: Threshold Segmentation Image

5. Conclusions and future work

In this work we investigated the application of different segmentation techniques in detecting kidney stones. The segmentation techniques under investigation are: edge based segmentation, watershed based segmentation and threshold based segmentation. Furthermore, depending on our experiments, we nominate watershed algorithms for detecting kidney stones. Future work may focus on applying other segmentation techniques to detect kidney stones, and improving the quality and efficiency of a reasonable analysis algorithm. Another interesting work is to expand the analysis region to apply different segmentation techniques to be used for diagnosis and follow-up of different kidney abnormalities. These abnormalities comprise stone disease, kidney cysts, hydronephrosis (blockage of urine), congenital anomalies, as well as urinary tract tumors.

References

- [1] A. Altintas, C. Unsalan, A. Keskin, F. Yencilek, *Detection of kidney stones from X-ray images*, 15th National Biomedical Engineering Meeting, 2010, 320-328.
- [2] M.R. Banham, A.K. Katsaggelos, *Spatially Adaptive Wavelet-Based Multi-scale Image Restoration*, IEEE Trans. Image Processing, 5 (1996), 619-634.
- [3] S. Beucher, et al., *Road segmentation by watershed algorithms*, Proceedings of the Pro-art vision group Prometheus workshop, 1990, 212-246.
- [4] J.P. Blandy, M. Singh, *The case for a more aggressive approach to staghorn stones*, Journal of Urology, 115 (1976), 505-506.

- [5] F.L. Coe, A. Evan, E. Worcester, *Kidney stone disease*, Journal of Clinical Investigation, 115 (2005), 2598-2608.
- [6] V.K. Dehariya, S.K. Shrivastava, R.C. Jain, *Clustering of image data set using K-means and fuzzy K-means algorithms*, International Conference on Conference on Computational Intelligence and Communication Networks (CICN), 386-391.
- [7] S. Ebrahimi, V.Y. Mariano, *Image quality improvement in kidney stone detection on computed tomography images*, Journal of Image and Graphics, 3 (2015), 40-46.
- [8] R.E. Gonzalez, *Digital image processing*, Pearson Education, 2002.
- [9] A. Hamed, B. Fei, *Automatic 3D Segmentation of the Kidney in MR images using wavelet feature extraction and probability shape model*, Proceedings of SPIE, 2013, 8314-8326.
- [10] Kidney Stones, Michigan University: Michigan Medicine, 2018, Retrieved from: <https://www.uofmhealth.org/conditions-treatments/adult-urology/kidney-stones>.
- [11] P. Natarajan, B.P. Singh, S. Dwivedi, S. Shraiya Nancy, *Kidney Segmentation in CT-Scan Image*, International Journal of Scientific and Engineering Research, 4 (2013), 221-225.
- [12] A. Petrik, K. Sarica, A. Skolarikos, M. Straub, C. Seitz, *Urolithiasis EAU guidelines*, 2016, Retrieved from: <https://uroweb.org/wp-content/uploads/EAU-Guidelines-Urolithiasis-2016-1.pdf>
- [13] S.N. Rous, W.R. Turner, *Retrospective study of 95 patients with staghorn calculus disease*, Journal of Urology, 118 (1977), 902904.
- [14] G. Sanchez, V. Vidal, V. Gumersindo, V. Mayo, R. Rodenas, *Efficient image segmentation using partial differential equations and morphology*, Annual International Conference of the IEEE Engineering in Medicine and Biology Society, 2012, 4382-4385.
- [15] I. Tulin, P. Das, *Computer-aided Kidney segmentation on abdominal CT images using fuzzy based denoising for Gaussian noise*, International Journal of Neuroscience, 5 (2017), 59-65.
- [16] R. Vasanthselvakumar, M. Balasubramanian, S. Palanivel, *Pattern analysis of Kidney diseases for detection and classification using ultrasound B-mode images*, International Journal of Pure and Applied Mathematics, 117 (2017), 635-653.

- [17] K. Viswanathand, R. Gunasundari, *Analysis and implementation of Kidney stone detection by reaction diffusion level set segmentation using xilinx system generator on FPGA*, VLSI Design, 2015, 1155-1165.
- [18] K. Youngwoo, et al., *Automated segmentation of Kidneys from MR images in patients with autosomal dominant polycystic Kidney disease*, Clinical Journal of the American Society of Nephrology: CJASN, vol. 11 (2016), 576-584.

Accepted: 20.12.2018